

1. Discuss and describe the following body orientation/directional terms in a way that will help you know what they mean:

superior: _____

inferior: _____

cranial: _____

caudal: _____

anterior: _____

posterior: _____

ventral: _____

dorsal: _____

medial: _____

lateral: _____

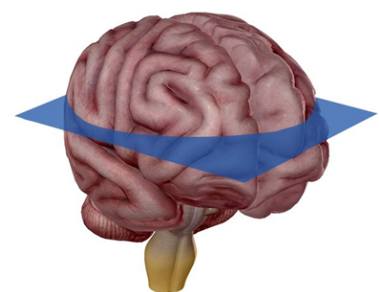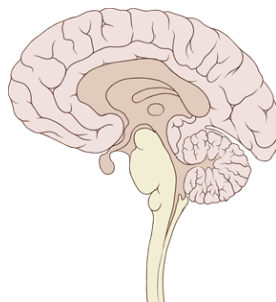
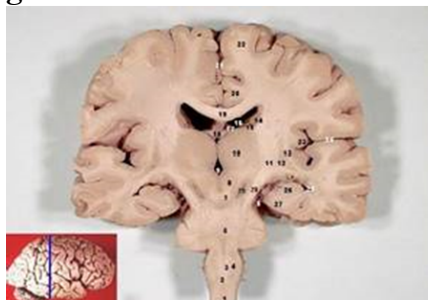
proximal: _____

distal: _____

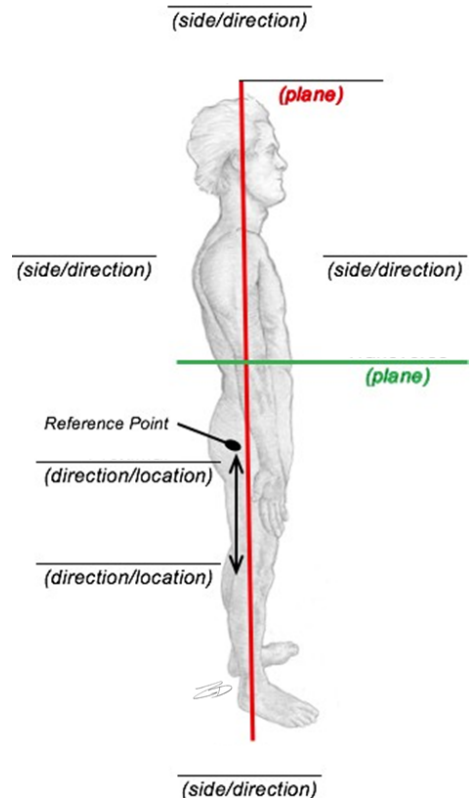
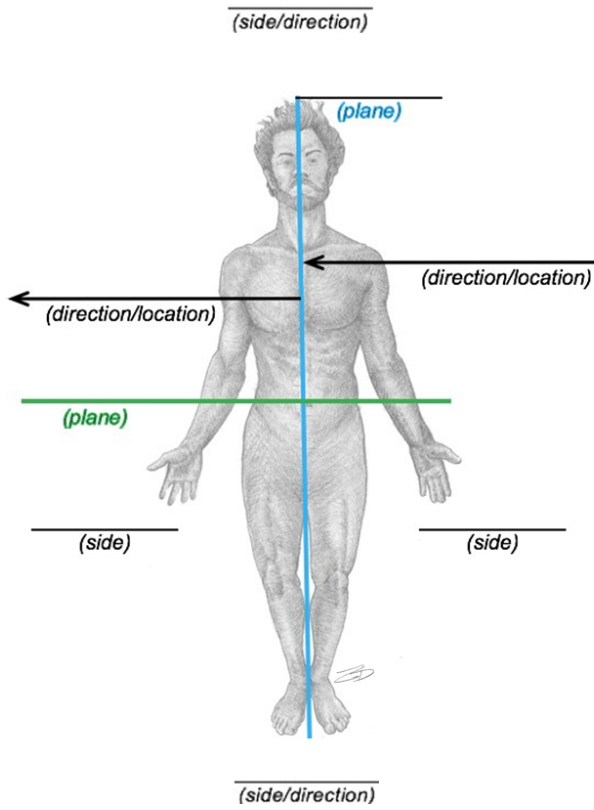
superficial: _____

deep: _____

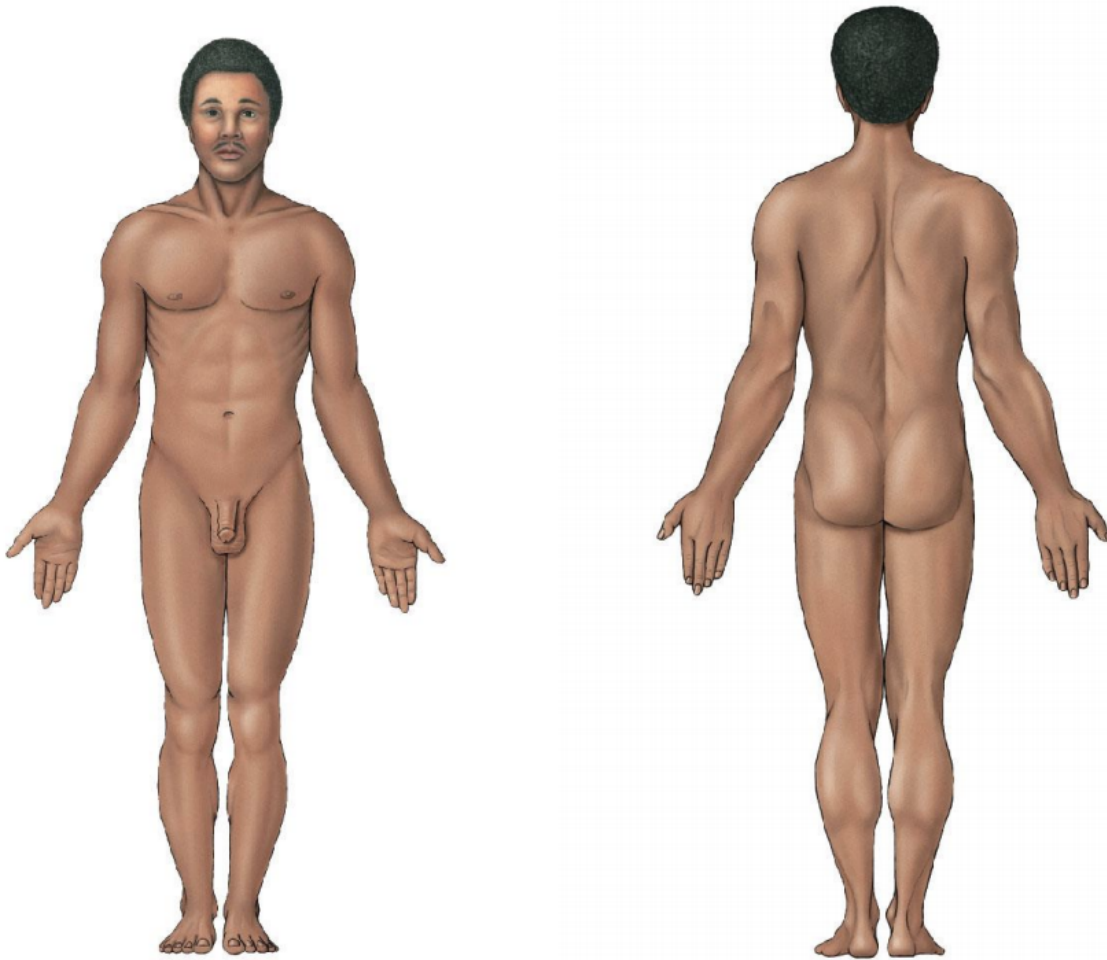
2. Name the type of section performed in the brain shown. Write your answers on the space given.



3. Label the two images below with the appropriate anatomical planes and directional terms:



4. Label the following images using the body regions listed in the table below:



Axial	Head	Upper Limb	Lower Limb
Cervical	Cephalic	Acromial	Gluteal
Thoracic	Cranial	Axillary	Inguinal
Sternal	Facial	Brachial	Femoral
Mammary	Frontal	Antecubital	Patellar
Abdominal	Ocular	Olecranal	Popliteal
Umbilical	Nasal	Antebrachial	Crural
Dorsal	Otic	Carpal	Sural
Lumbar	Buccal	Manual	Tarsal
Pelvic	Oral	Palmar	Calcaneal
Pubic	Mental	Pollex	Pedal
Coxal	Lingual	Digital	Plantar

5. Fill in the common term for each anatomical region.

Adjective Form	English Term
Cervical	
Thoracic	
Sternal	
Mammary	
Abdominal	
Umbilical	
Dorsal	
Lumbar	
Pelvic	
Pubic	
Coxal	
Cephalic	
Cranial	
Facial	
Frontal	
Frontal	
Ocular	
Otic	
Nasal	
Buccal	
Oral	
Mental	
Lingual	

Acromial	
Axillary	
Brachial	
Antecubital	
Olecranal	
Antebrachial	
Carpal	
Manual	
Palmar	
Pollex	
Digital	
Gluteal	
Inguinal	
Femoral	
Patellar	
Popliteal	
Crural	
Sural	
Calcaneal	
Pedal	
Plantar	

Adjective Form	Noun Form	English Term
----------------	-----------	--------------

Cervical		
Thoracic		
Sternal		
Mammary		
Abdominal		
Umbilical		
Dorsal		
Lumbar		
Pelvic		
Pubic		
Coxal		
Cephalic		
Cranial		
Facial		
Frontal		
Ocular		
Nasal		
Otic		
Buccal		
Oral		
Mental		
Lingual		
Acromial		
Axillary		
Brachial		
Antecubital		
Olecranal		
Antebrachial		
Carpal		
Manual		
Palmar		

Pollex		
Digital		
Gluteal		
Inguinal		
Femoral		
Patellar		
Popliteal		
Crural		
Sural		
Tarsal		
Calcaneal		
Pedal		
Plantar		